

Unstable Distal Radius Fractures Treated by Volar Locking Anatomical Plates

ANTO JOSE¹, SHISHIR MURUGHARAJ SURANIGI², PASCAL NOEL DENIESE³,
ABEY THOMAS BABU⁴, KANAGASABAI RENGASAMY⁵, SYED NAJIMUDEEN⁶

ABSTRACT

Introduction: Fracture of the distal end of radius represents the most common fracture of the upper extremity accounting for approximately 16-20% of all fractures. Plating is now emerging as the gold standard for management of distal radius fractures due to increased rate of complications such as malunion, subluxation/dislocation of distal radio-ulnar joint or late collapse of fracture. Procedures such as closed reduction and cast immobilization, ligamentotaxis with external fixator and percutaneous pin fixation are no longer acceptable.

Aim: The purpose of the study was to evaluate the functional and radiological outcome of unstable distal radius fractures treated with the volar locking plate.

Materials and Methods: We reviewed 53 patients from January 2011 to December 2015, treated for unstable distal radius fractures using a volar locking compression plate. Standard radiographic and clinical assessment after 12 months (range 12-

16 months) were measured and final functional and radiological outcome were assessed using the Modified Mayo wrist scoring system and Sarmiento's modification of Lindstorm criteria respectively.

Results: There were 42 males and 11 females with an average age of 39.12±31.78 years (18-71 years). At the end of 12 months, 36 patients had an excellent radiological outcome and 10 patients had good radiological outcome as per Sarmiento's modification of Lindstorm criteria. Eleven patients had an excellent functional outcome and 26 patients had a good functional outcome as per modified Mayo wrist scoring system. There was one case of superficial wound infection which subsided with intravenous antibiotics.

Conclusion: The volar locking plate fixation helps in early mobilization of the wrist, restores anatomy, allows early return to function, prevents secondary loss of reduction and hence is an effective treatment for unstable fractures of the distal radius.

Keywords: Distal radio ulnar joint, Intra-articular fractures, LCP, Unstable fractures, Volar approach

INTRODUCTION

Fracture of the distal end of radius represents the most common fracture of the upper extremity accounting for 16-20% of all fractures treated by orthopaedic surgeons world-wide [1,2]. Due to increased rate of complications such as malunion, subluxation/dislocation of distal radio-ulnar joint or late collapse of fracture with procedures such as closed reduction and cast immobilization, ligamentotaxis with external fixator and percutaneous pin fixation are no longer acceptable. Furthermore, these procedures often result in poor functional and cosmetic outcome [3,4]. The residual deformity of wrist adversely affects the hand function causing pain, limitation of supination and pronation, and decreased grip strength as a result of radio-carpal and distal radio-ulnar joint arthritis [5,6].

Hence, anatomical articular reduction and stable fixation with or without bone grafting, greatly reduces the incidence of post-traumatic osteoarthritis and stiffness. The accuracy of fracture reduction correlates directly to the final outcome [7-9]. The advantages of plate osteosynthesis are direct fracture reduction, stable rigid fixation, the possibility of immediate post-operative mobilization and early return to function [10-12]. With the advent of Locking Compression Plate (LCP), the bone fragments can be held together in place even after union to prevent secondary displacement of unstable fractures, especially in elderly osteoporotic bone [13-15].

Hence, this study evaluated the functional and radiological outcome of internal fixation with volar plate osteosynthesis in the management of unstable fractures of distal end radius.

MATERIALS AND METHODS

We reviewed 53 patients from January 2011 to December 2015, treated for unstable distal radius fractures using a volar locking

compression plate in our institution who fulfilled the inclusion criteria. The institutional ethics committee approval for the study was granted (IEC: RC/14/43).

Instability was established using the Lafontaine's criteria for unstable fractures of the distal end of radius [16]. He suggested 5 factors that indicated instability. They were initial dorsal angulation greater than 20 degrees, dorsal comminution, radio carpal intra-articular involvement, associated ulna fractures, and age greater than 60 years.

Inclusion criteria: According to Lafontaine et al., fractures presenting with three or more of these factors correlated with loss of position despite cast immobilization and were thus considered unstable. Exclusion criteria included any fracture older than 2 weeks, distal radius fractures extending to shaft of radius, concomitant fractures of ipsilateral limb, open fractures, patients with less than 1 year of follow-up and any previous fractures around the wrist.

After obtaining an informed written consent, patients fulfilling the inclusion criteria were taken up for open reduction and internal fixation with plate osteosynthesis. Out of the 53 patients, 30 of them underwent general anaesthesia and rest 23 underwent ultrasound guided brachial plexus block. Tourniquet was used in all the cases. Through anterior Henry's approach /Ellis approach, the fracture was approached. The pronator quadratus was detached sub-periosteally from the lateral border of radius. The distal part of the incision was curved laterally to gain better access to the articular surface. Anatomic reduction was achieved using manual ligamentotaxis or dis-impacting the fracture fragments using osteotome. A volar 3.5 mm locking titanium plate (Sharma surgicals, India) was used. The reduction and screw placement were checked under image intensifier. Additional stabilization, if found

necessary, was done either with k-wires or with 4 mm cancellous screws. At the end of the procedure, the detached end of the pronator quadratus was reattached to the edge of brachioradialis to provide coverage for the distal plate. Carpal tunnel was not decompressed in any of our cases. Bone grafting was done for severely comminuted and osteoporotic fractures. Distal Radio-Ulnar Joint (DRUJ) instability was assessed in all cases intraoperatively after the fixation of the distal radius by ballotment test, with the forearm in a neutral position. DRUJ instability was suspected if there was a soft endpoint with an increase in the antero-posterior translation of 5–10 mm as compared to the uninjured wrist [17]. In such cases, DRUJ was temporarily transfixed with radio-ulnar K-wire for a period of 4 weeks and the wire was removed in the out-patient department. All the patients were operated via the same approach as described above by a single team of surgeons comprising of a senior professor, an associate professor and 2 assistant professors.

Post-operatively, radiographs were taken to evaluate the reduction and fixation. Wrist was immobilized in a short below elbow plaster splint till suture removal. During this period, patients were instructed to do active and passive finger motion exercises. After splint removal patients were started on wrist and finger range of motion exercises. For those with DRUJ fixation, forearm rotation was restricted for a total of four weeks post-operatively. Most patients were given a home physiotherapy program but patients who were 65 years and above were advised twice a week visit to physiotherapy department for supervised mobilization. Strenuous use of the hand including heavy weight lifting was not allowed for 12 weeks after surgery. All patients were followed up at 1 month, 3 months, 6 months and at the end of 1 year post-operatively. At the time of follow-up, antero-posterior and lateral view radiographs of both wrists were taken on a single exposure for analysis. Radiological outcome was assessed as per Sarmiento's modification of Lindstorm criteria [18] and functional outcome using the modified Mayo wrist scoring system [19].

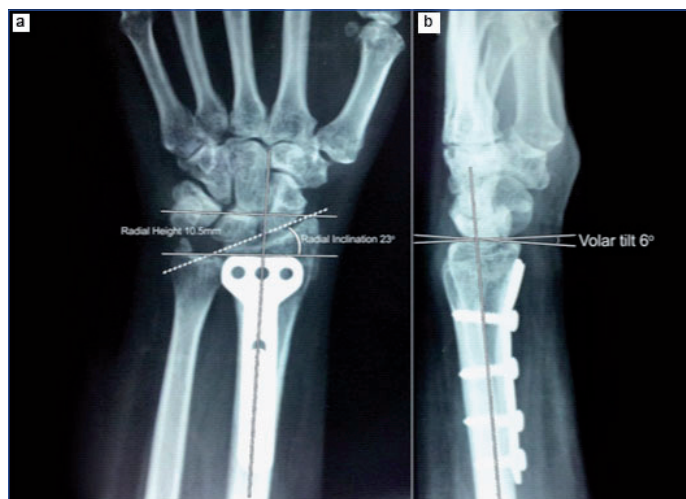
RESULTS

Out of the 53 patients with unstable distal end radius fracture, 42 were males and 11 females with an average age of 39.12±31.78 years (18–71 years). Road traffic accident was the most common mode of injury accounting for 35 of the distal radius fractures. Rest 18 of them sustained a fall resulting in distal radius fracture. Thirty of the 53 patients were right hand dominant [Table/Fig-1]. All patients were followed up for a minimum duration of 12 months (range: 12-32 months). All fractures were classified according to AO/OTA classification. There were 9 23-A3 fractures, 11 23-B2 fractures, 15 23-B3 fractures, 10 23-C2 fractures and 8 23-C3 fractures. 11 patients had associated ulnar styloid fracture (1 23-B2, 2 23-B3, 3 23-C2 and 5 23-C3). None of them underwent ulnar styloid fixation. DRUJ instability was diagnosed in seven (13.20%; 2 23-A3, 1 23-B2, 1 23-B3, 1 23-C2 and 2 23-C3) patients intraoperatively. They underwent additional radio-ulnar k-wire fixation. The radiological parameters such as palmar tilt, radial height, radial inclination and ulnar variance of the affected wrist and normal side were tabulated preoperatively and post-operatively at each visit.

In addition to plating, 5 patients underwent additional k-wiring for radial styloid fixation. K-wire was removed in the Outpatient Department (OPD) after radiological fracture union. Primary bone grafting was done in 5 cases (1 23-B3, 2 23-C2 and 2 23-C3). Out of the 53 cases, 51 of them united radiologically with a mean duration of 3.34 months (range: 2.5-4.2 months). In 2 cases, there was a delay in union. X-ray images showed sub-articular and metaphyseal defect for which bone grafting was done. Both the fractures eventually united at 15 and 18 weeks, respectively. The average postoperative radial inclination, radial height, palmar tilt and ulnar variance, calculated at 7 to 12 weeks was found

Mean age at presentation	39.12±31.78 years (18–71 years)
Sex	Male - 42 Female - 11
Mode of injury	Road Traffic Accident - 35 Fall - 18
Type of fracture	A3 - 09 B2 - 11 B3 - 15 C2 - 10 C3 - 08
Hand dominance	Right - 30 Left - 23

[Table/Fig-1]: Clinical profile of patients.



[Table/Fig-2]: Radiographic analysis of a 35-year-old male patient with AO 23-B2 distal radius fracture at the end of 1 year: (a) Radial inclination of 23 degrees and radial height of 10.5 mm on Antero-posterior view; (b) Palmar tilt of 6 degrees on lateral view radiograph.

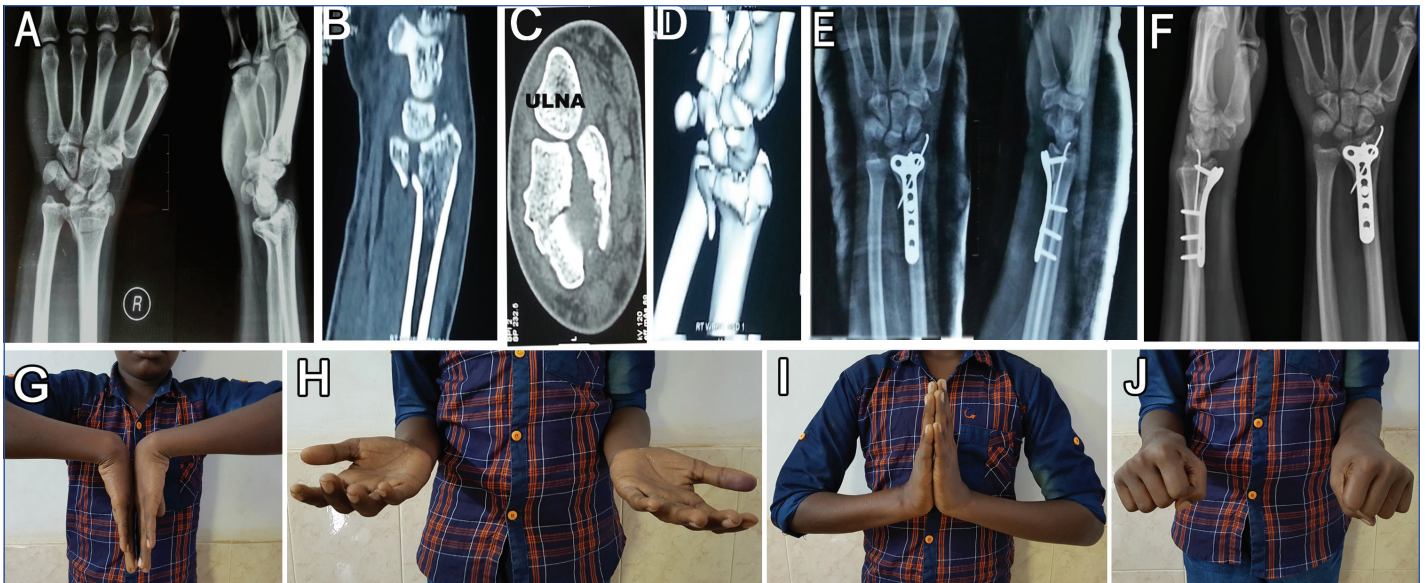
Parameters	Postoperatively (7–12 weeks)	At 1 year follow-up
Radial inclination	21.03±4.25 degrees	20.94±4.44 degrees
Radial Height	10.11±1.64mm	10.03±1.20 mm
Palmar tilt	9.64±5.94 degrees	9.51±5.23 degrees
Ulnar variance	-0.27±0.67 mm	-0.15±1.99 mm

[Table/Fig-3]: Radiological parameters.

to be 21.03±4.25 degrees, 10.11±1.64mm, 9.64± 5.94 degrees and -0.27±0.67 mm respectively. At the end of 1 year of follow-up, the average radial inclination, radial height, palmar tilt and ulnar variance changed to 20.94±4.44 degrees, 10.03±1.20 mm, 9.51±5.23 degrees and -0.15±1.99 mm respectively [Table/Fig-2,3]. No significant difference ($p < 0.001$) in the radiological parameters were noted at the end of 1 year follow-up, indicating no further significant collapse of fracture [Table/Fig-4].

The average wrist range of motion at the end of 1 year of follow-up was 61.13± 12.88 degrees flexion (range 35 to 85 degrees) and 50.66±18.43 degrees extension (range 35 to 90 degrees). The average forearm range of motion was 77.43±11.40 degrees supination (range 50 to 90 degrees) and 84.37±5.35 degrees pronation (range 70 to 90 degrees) at 1 year of follow-up. Hand grip strength (compared to opposite side), as assessed by a hand held dynamometer improved from 55.45±21.55% (range 40 to 90%) at 6 weeks follow-up to 89.00±4.55% (range 75 to 100) at 1 year follow-up, respectively [Table/Fig-5,6].

At the end of 1 year follow-up, 11(20.75%) patients had excellent outcome, 26(49.06%) had good outcome, 10 (18.87%) patients had satisfactory outcome and 6(11.32%) patients had poor outcome as per the modified Mayo wrist scoring system [Table/Fig-7]. These 6 patients (1 23-B3, 1 23-C2 and 4 23-C3) had poor functional outcome owing to their complications and non-



[Table/Fig-4]: Preoperative radiographs: (a) of 19-year-old boy with AO 23-C3 distal radius fracture. CT scan; (b-d) showing the intra-articular comminution; (e) Immediate postoperative radiographs showing good reduction of fragments; (f) Radiographs at the end of 1 year showing no further collapse of fracture and restored radiological parameters; (g-j) showing excellent functional outcome.

Parameters	6 weeks post-op	1 year follow-up
Flexion	40.14± 14.11 degrees	61.13±12.88 degrees
Extension	29.12±7.44 degrees	50.66±18.43 degrees
Supination	54.95±10.01 degrees	77.43±11.40 degrees
Pronation	74.15±8.14 degrees	84.37±5.35 degrees
Grip strength (compared to opposite side)	55.45±21.55%	89.00±4.55%

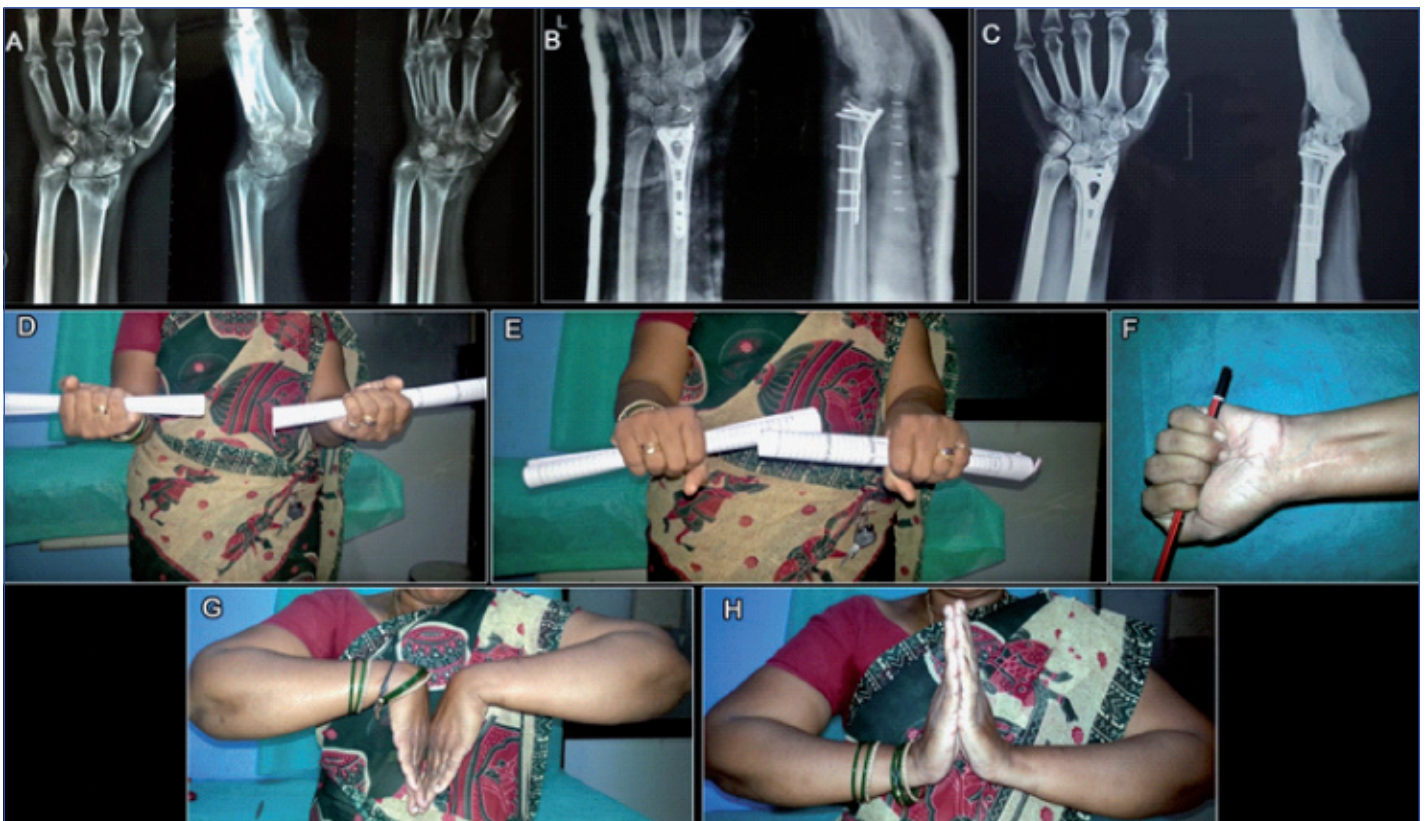[Table/Fig-5]: Functional evaluation of patients at the end of 6 weeks post-op and 1 year follow-up.

compliance to postoperative rehabilitation. Overall, 8 patients had complications [Table/Fig-8]. There were no cases of tendon ruptures or non-union in our study.

On radiological scoring by Sarmiento's modification of Lindstrom criteria, 36(67.92%) patients had excellent results, 10(18.87%) patients had good results and 7(13.21%) patients had fair results. Fair results were attributed to poor reduction and alignment of fracture fragments.

DISCUSSION

An anatomical reduction of the articular surface with a stable fixation is the main goal in the treatment of intra-articular distal radius fractures. Improper reduction or residual intra-articular incongruity leads to secondary arthritis and poor functional outcome in the long term [5,6]. Various treatment modalities have been described for distal radius fracture fixation. Treatment options range from closed reduction and cast application to open reduction with plates and



[Table/Fig-6]: Preoperative radiographs: (a) of 34-year-old lady with AO 23-B2 distal radius fracture. (b) Immediate postoperative radiographs showing good reduction of fragments with plate in-situ; (c) Radiographs at the end of 15 months showing no further collapse of fracture and restored radiological parameters; (d-h) showing excellent functional outcome.

Scoring System	1 year Follow-up
Modified Mayo wrist scoring system	Excellent- 11 (20.75%) Good- 26 (49.06%) Satisfactory- 10 (18.87%) Poor- 06 (11.32%)
Sarmiento's modification of Lindstrom criteria	Excellent- 36 (67.92%) Good- 10 (18.87%) Fair- 07 (13.21%) Poor- 0

[Table/Fig-7]: Functional and radiological outcome of unstable distal radius fractures.

screws. Plating allows direct visualization of fracture fragments and restoration of the anatomy, decreased morbidity by allowing early mobilization, and early return of wrist function. Locking plates address intra-articular and metaphyseal comminution and are very helpful in osteoporotic fractures preventing late collapse of fracture fragments. Biomechanical studies comparing volar fixed-angle locking plates with that of conventional dorsal plates report volar fixed-angled plates to be superior in terms of their strength. Dorsal plating of distal radius has not gained popularity due the fact that, inspite of dorsal plating, the volar collapse of fracture occurred [20]. Complications associated with plating include risk of infection as compared to closed procedures, tendon irritation or rupture. These may warrant implant removal in some cases.

DRUJ instability was previously recognized as a poor prognostic factor in the management of distal radius fractures. However, studies suggest that anatomically reduced and rigidly fixed distal radius fractures with locking plates have no significant difference in the final functional outcome between patients treated with and without ulnar styloid fractures, despite the degree of displacement and the location of the fractures [21]. In our study, seven (13.20%; 2 23-A3, 1 23-B2, 1 23-B3, 1 23-C2 and 2 23-C3) patients, diagnosed to have DRUJ instability intraoperatively underwent additional radio-ulnar K-wire fixation. The K-wire was removed in the Out-Patient Department after 4 weeks. These patients had reduced pronation at 6 weeks of follow-up but there was no difference compared to the non-fixed group at the end of 3 months. DRUJ fixation had no negative impact on the outcome of the study at the end of 1 year follow-up.

Studies have been done to demonstrate the advantages of fixation of ulnar styloid fractures along with distal radius fractures, but not many have been successful. The results have been variable [21]. In a study done by Zenke Y et al., the good functional outcome of distal radius fractures did not depend on the fixation of ulnar styloid [22]. They concluded that most of the ulnar styloid fractures healed with fibrous union and remained asymptomatic. Jae Kwang Kim et al., studied ulnar styloid fractures in seventy-six (55%) of the 138 patients and they concluded that an accompanying ulnar styloid fracture in patients with stable fixation of a distal radial fracture has no apparent adverse effect on wrist function or stability of the distal radioulnar joint [23].

In our study, the dominant side, when injured recovered early, with grip strength 95% of the contra lateral side at 6 months follow-up

Complication	Number of cases	Intervention	Functional outcome (At 1 year follow-up)
1. Screw penetration into the joint due to excessive fracture collapse in spite of primary bone grafting	1	Implant exit was done after fracture union at 3 months follow-up.	Fair
2. Significant prominence of screws noted on the postoperative x-rays.(more than 2 threads protruding out of the dorsal cortex).	4	Two patients had pain on palmar flexion of the wrist. They underwent implant removal at 6th month and 8th month respectively. Rest two were asymptomatic. No further intervention was done.	Excellent-2 patients Good-2 patients
3. Superficial wound infection	1	Intravenous antibiotics for 10 days. Infection subsided.	Excellent
4. Persistent pain with decreased range of motion at the wrist.	2	Implant exit was done after fracture union at 6 months and 9 months respectively. VAS improved from 7 to 1 in one case and in the other case remained at 5 even after implant exit. X-ray of this patient showed reduction of radio-carpal joint space, erosions and juxta-articular cysts suggestive of radio-carpal arthritis. She opted no further treatment.	Satisfactory-1 patient Poor-1 patient

[Table/Fig-8]: Complications with their functional outcome.

and remained the same at 1 year of follow-up. Grip strength of the non-dominant injured side only reached 82% of the normal side even at 1 year of follow-up. Pronation improved more rapidly than supination at 6 weeks of follow-up but both returned to near normal at the 1 year of assessment. No significant difference ($p < 0.001$) in the radiological parameters were noted at the end of 1 year as compared to 6 weeks of follow-up, indicating that the fracture fixation was rigid and no further significant collapse of the fracture occurred.

At the end of 1 year follow-up, out of the 53, 37(69.81%) patients had excellent to good results, compared to 6(11.32%) patients who had poor outcome as per the modified Mayo wrist scoring system owing to the complications mentioned above. The limitations of our study were lack of controls and non- uniformity of fracture pattern.

CONCLUSION

We conclude that, non-fixation of ulnar styloid fracture did not have a negative impact on the outcome of the study. DRUJ stabilization for instability with K-wire for 4 weeks resulted in favourable outcome. For unstable fractures of the distal end of radius, volar locking plate osteosynthesis is a valid and effective treatment option ensuring a successful functional and radiological outcome.

CONFLICT OF INTEREST

The authors report no conflict of interest concerning the materials or methods used in this study or the findings specified in this paper.

CONSENT

Written informed consent was obtained from all the patients for publication of this report and accompanying images. This study has the approval of the institutional ethics committee.

REFERENCES

- [1] Johnson NA, Cutler L, Dias JJ, Ullah AS, Wildin CJ, Bhowal B. Complications after volar locking plate fixation of distal radius fractures. *Injury*. 2014;45(3):528–33.
- [2] Fok MW, Klausmeyer MA, Fernandez DL, Orbay JL, Bergada AL. Volar plate fixation of intra-articular distal radius fractures: a retrospective study. *J Wrist Surg*. 2013;2(3):247–54.
- [3] Arora R, Lutz M, Deml C, Krappinger D, Haug L, Gabl M. A prospective randomized trial comparing non-operative treatment with volar locking plate fixation for displaced and unstable distal radial fractures in patients sixty-five years of age and older. *J Bone Joint Surg Am*. 2011;93(23):2146–53.
- [4] Anakwe R, Khan L, Cook R, McEachan J. Locked volar plating for complex distal radius fractures: Patient reported outcomes and satisfaction. *J Orthop Surg Res*. 2010;5:51.
- [5] Fowler JR, Ilyas AM. Prospective evaluation of distal radius fractures treated with variable-angle volar locking plates. *J Hand Surg Am*. 2013;38(11):2198–203.
- [6] Berglund LM, Messer TM. Complications of volar plate fixation for managing distal radius fractures. *J Am Acad Orthop Surg*. 2009;17(6):369–77.
- [7] Mackenney J, McQueen MM, Elton R. Prediction of instability in distal radial fractures. *J Bone Joint Surg Am*. 2006;88(9):1944–51.
- [8] Diaz-Garcia RJ, Oda T, Shauver MJ, Chung KC. A systematic review of outcomes and complications of treating unstable distal radius fractures in the elderly. *J Hand Surg Am*. 2011;36(5):824–35.
- [9] Arora R, Lutz M, Hennerbichler A, Krappinger D, Espen D, Gabl M. Complications following internal fixation of unstable distal radius fracture with a palmar locking-plate. *J Orthop Trauma*. 2007; 21(5):316–22.

- [10] Willis AA, Kutsumi K, Zobitz ME, Cooney, WP III. Internal fixation of dorsally displaced fractures of the distal part of the radius: a biomechanical analysis of volar plate fracture stability. *J Bone Joint Surg Am.* 2006;88(11):2411-17.
- [11] Gondusky JS, Carney J, Erpenbach J, Robertson C, Mahar A, Oka R, et al. Biomechanical comparison of locking versus nonlocking volar and dorsal T-plates for fixation of dorsally comminuted distal radius fractures. *J Orthop Trauma.* 2011;25(1):44-50.
- [12] Bentohami A, de Buriel K, de Korte N, van den Bekerom MP, Goslings JC, Schep NW. Complications following volar locking plate fixation for distal radial fractures: a systematic review. *J Hand Surg Eur.* 2014;39(7):745-54.
- [13] Jakob M, Rikli DA, Regazzoni P. Fractures of the distal radius treated by internal fixation and early function. A prospective study of 73 consecutive patients. *J Bone Joint Surg Br.* 2000;82(3):340-44.
- [14] Rein S, Schikore H, Schneiders W, Amlang M, Zwipp H. Results of dorsal or volar plate fixation of AO type C3 distal radius fractures: a retrospective study. *J Hand Surg Am.* 2007;32(7):954-61.
- [15] Figl M, Weninger P, Liska M, Hofbauer M, Leixnering M. Volar fixed-angle plate osteosynthesis of unstable distal radius fractures: 12 months results. *Arch Orthop Trauma Surg.* 2009;129(5):661-69.
- [16] Lafontaine M, Hardy D, Delince P. Stability assessment of distal radius fractures. *Injury.* 1989;20(4):208-10.
- [17] Lindau T, Hagberg L, Adlercreutz C, Jonsson K, Aspenberg P. Distal radioulnar instability is an independent worsening factor in distal radial fractures. *Clin Orthop Relat Res.* 2000;(376):229-35.
- [18] Gupta DK, Kumar G. Ulnocarpal stabilization in the management of comminuted fractures distal end radius. *Indian J Orthop.* 2009;43(1):55-61.
- [19] Amadio PC, Berquist TH, Smith DK, Ilstrup DM, Cooney WP 3rd, Linscheid RL. Scaphoid malunion. *J Hand Surg Am.* 1989;14(4):679-87.
- [20] Wei J, Yang TB, Luo W, Qin JB, Kong FJ. Complications following dorsal versus volar plate fixation of DRF: a meta-analysis. *J Int Med Res.* 2013;41(2):265-75.
- [21] Osada D, Viegas SF, Shah MA, Morris RP, Patterson RM. Comparison of different distal radius dorsal and volar fracture fixation plates: a biomechanical study. *J Hand Surg Am.* 2003;28(1):94-104.
- [22] Zenke Y, Sakai A, Oshige T, Moritani S, Nakamura T. The effect of an associated ulnar styloid fracture on the outcome after fixation of a fracture of the distal radius. *J Bone Joint Surg Br.* 2009;91(1):102-07.
- [23] Kim JK, Koh YD, Do NH. Should an ulnar styloid fracture be fixed following volar plate fixation of a distal radial fracture? *J Bone Joint Surg Am.* 2010;92(1):1-6.

PARTICULARS OF CONTRIBUTORS:

1. Resident, Department of Orthopaedics, Pondicherry Institute of Medical Sciences, Pondicherry, India.
2. Associate Professor, Department of Orthopaedics, Pondicherry Institute of Medical Sciences, Pondicherry, India.
3. Assistant Professor, Department of Orthopaedics, Pondicherry Institute of Medical Sciences, Pondicherry, India.
4. Assistant Professor, Department of Orthopaedics, Pondicherry Institute of Medical Sciences, Pondicherry, India.
5. Professor, Department of Orthopaedics, Pondicherry Institute of Medical Sciences, Pondicherry, India.
6. Professor and Head, Department of Orthopaedics, Pondicherry Institute of Medical Sciences, Pondicherry, India.

NAME, ADDRESS, E-MAIL ID OF THE CORRESPONDING AUTHOR:

Dr. Shishir Murugharaj Suranigi,
Associate Professor, Department of Orthopaedics, Pondicherry Institute of Medical Sciences, Pondicherry-605014, India.
E-mail: shishir100@gmail.com

Date of Submission: **Sep 11, 2016**

Date of Peer Review: **Oct 14, 2016**

Date of Acceptance: **Nov 01, 2016**

Date of Publishing: **Jan 01, 2017**

FINANCIAL OR OTHER COMPETING INTERESTS: None.